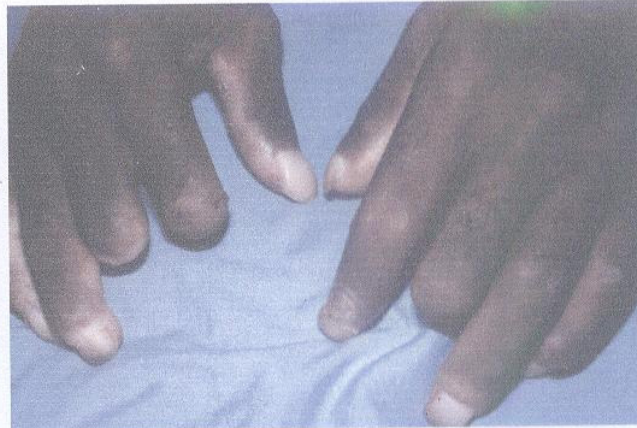
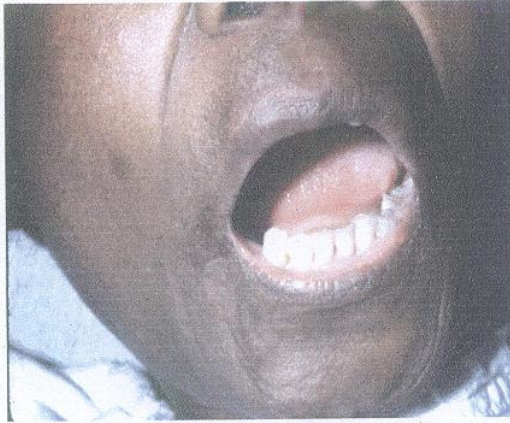
Photographs 1 and 2 show patient with scleroderma.

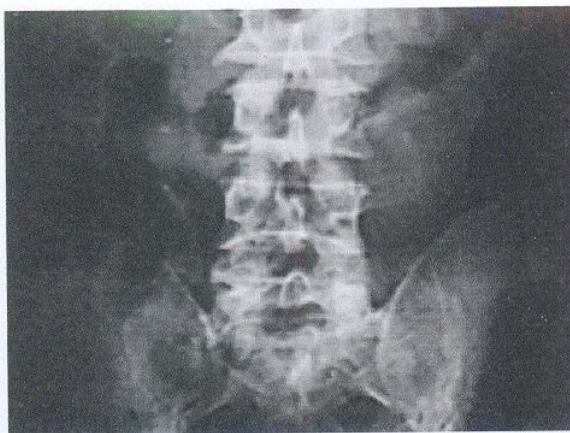


Fig. (3): Plain X- ray film of a patient with venous thrombosis

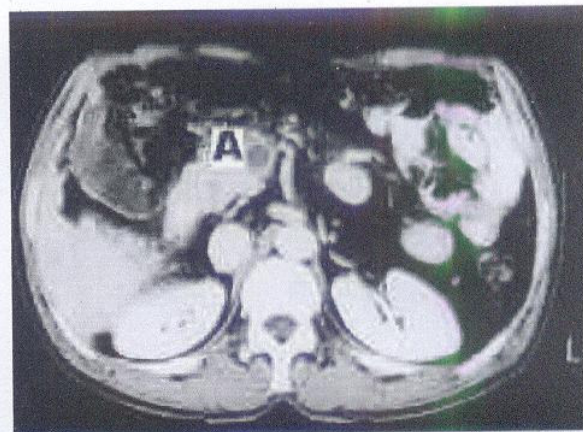


Fig. (4): CT scan showing filling defect (A) in superior mesenteric vein.

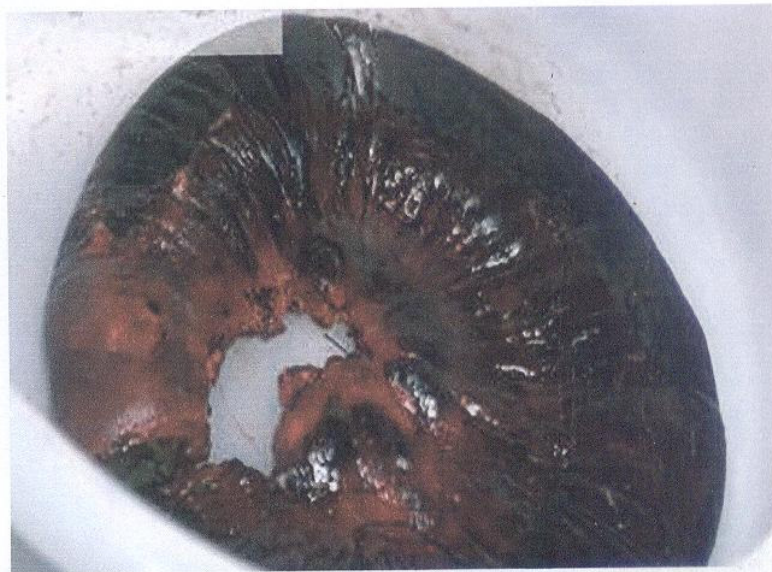

Fig. (5): Bowel gangrene due to venous occlusion